

## All You Need to Know About the Hidden C6-C7 Malformation That's Bringing Horses Down

What if you were to learn that your horse is living with a hidden malformation? A skeletal abnormality that could be affecting it every day, changing the way it moves, creating a string of other physical problems, and possibly underlying the hard-to-pinpoint problems you've been noticing for months or even years?

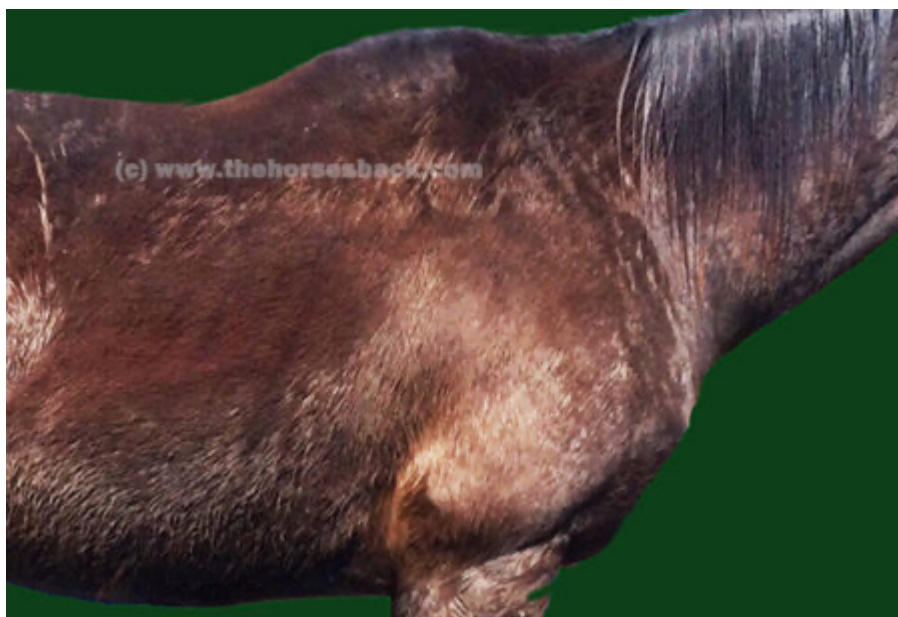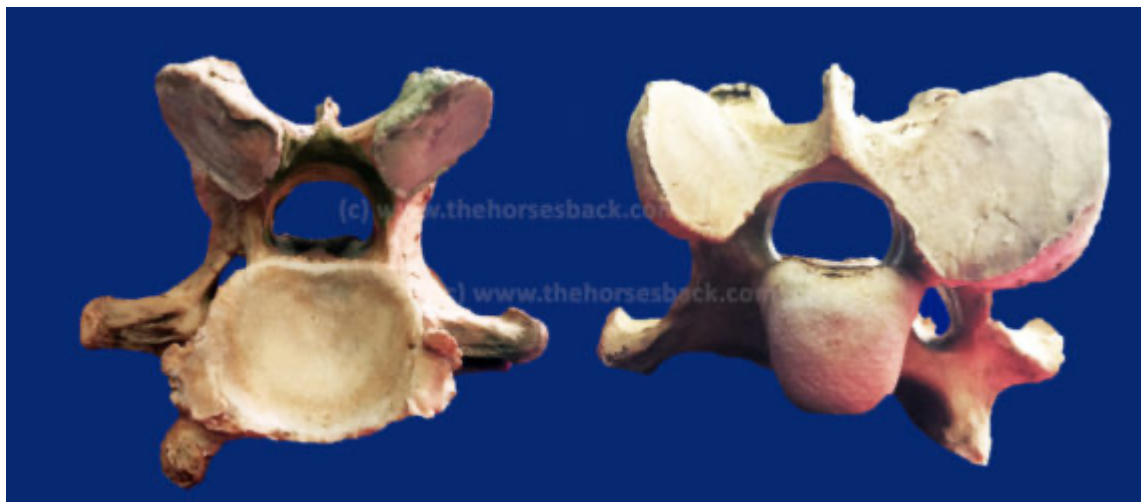And that might even be causing a level of inherent instability that could be putting the rider in danger?

Sadly, this isn't a hypothetical question. Instead it's a reality that is only now being slowly uncovered.

And like the proverbial stone rolling down a mountain, the issue is gathering momentum as the equine industry, owners, breeders and researchers learn about it.

<https://thehorsesback.com/c6-c7-malformation/>

Published: **Jul 16, 2017**

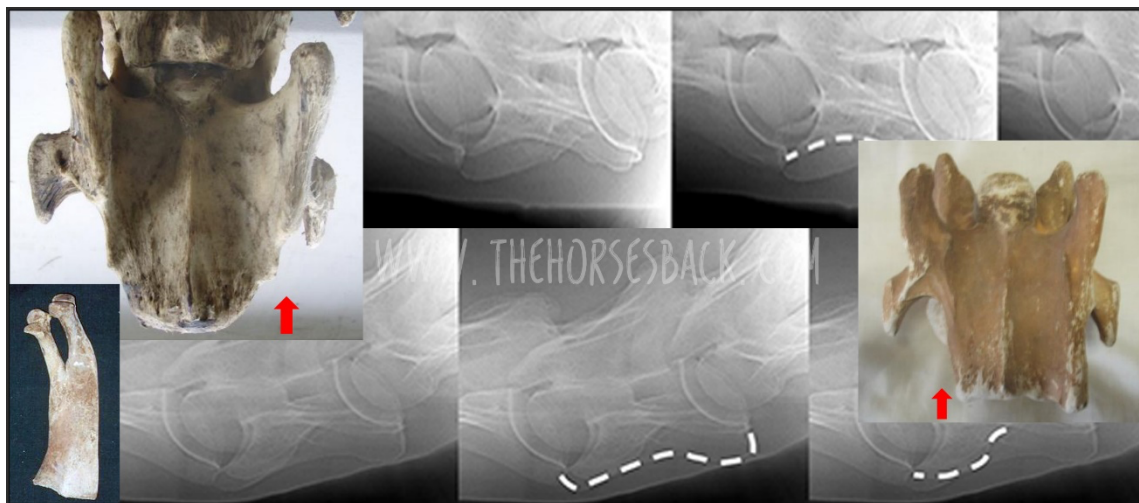


## By Popular Demand: Here's How You X-Ray for the C6-C7 Malformation

By Sharon May-Davis

### Abstract

In 2014, a published study based on dissections and skeletal examinations noted that 19:50 Thoroughbred horses had a congenital malformation of the 6th cervical vertebra (C6). In addition, it was found that in those 19 Thoroughbred horses expressing a congenital malformation of C6, 9 displayed a concurrent congenital malformation of the 7th cervical vertebra (C7). In this study, 3 Thoroughbred horses and 1 Thoroughbred type were clinically examined; 3 were radiographed for limb abnormalities and 2:3 radiographed for the congenital malformation of C6 and C7 prior to euthanasia. Upon dissection, 3:4 expressed a congenital malformation of C6 with 2:3 displaying a concurrent CM of C7. These 2 horses were positively radiographed for the CM of C6 and C7 prior to dissection. The radiographs of C6 were taken in direct lateral orientation with 0 degree of elevation and revealed the absence of the caudal ventral tubercle (CVT) of C6. Re-positioning the horse's forelimbs caudally with an outstretched neck, C7 was radiographed at a 30° oblique lateral angle in a cranial to caudal direction with 0 degree of elevation; the transverse process of C5 remained cranial to the beam. The caudal aspect of the plate was positioned medial the Cranial deep pectoral and rotated vertically to expand the field of view of the cervical vertebrae, whilst remaining perpendicular to the beam.



<https://thehorsesback.com/c6-xray/>

Published: Aug 16, 2017

## Why I Now Believe My Warmblood Gelding Had the C6-C7 Problem

*"I went through three years of horror..."*

So speaks a Warmblood owner, reflecting upon a truly dreadful period in her life. Like many other owners, she has gained belated understanding of her horse's problems after reading about research findings into the C6-C7 malformation led by Australian gross anatomist, Sharon May-Davis.

Sadly, this is a bittersweet moment: there is a temporary relief as everything finally makes sense, yet with it comes the realisation that there is nothing that can be, or could have been, done for a treasured horse bearing the more extreme version of this malformation.

Here, Diana from Michigan, USA, gives her story of the desperation and - ultimately - heartache she experienced when trying to find out what was wrong with her horse of a lifetime, a young Oldenburg gelding, "the kindest horse I ever had".



<https://thehorsesback.com/c6-warmblood/>

Published: Nov 16, 2017